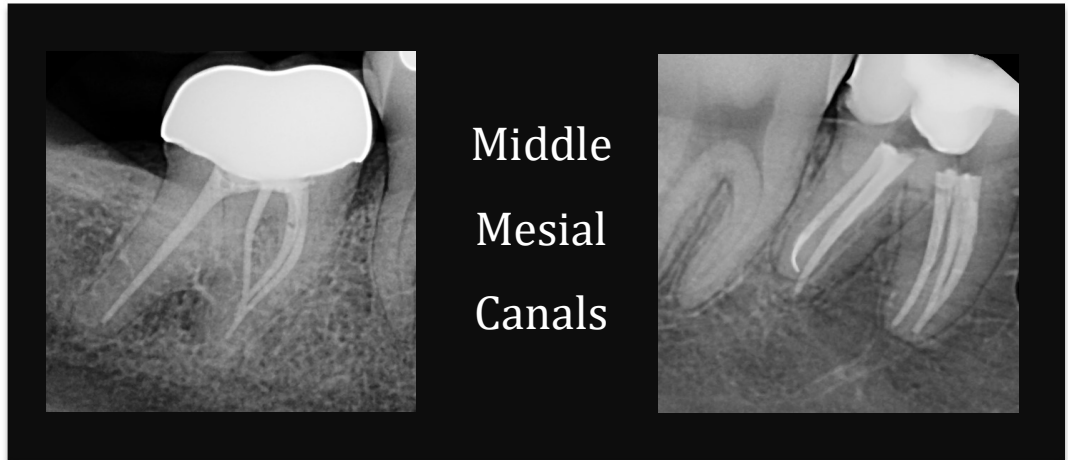


Root Tips

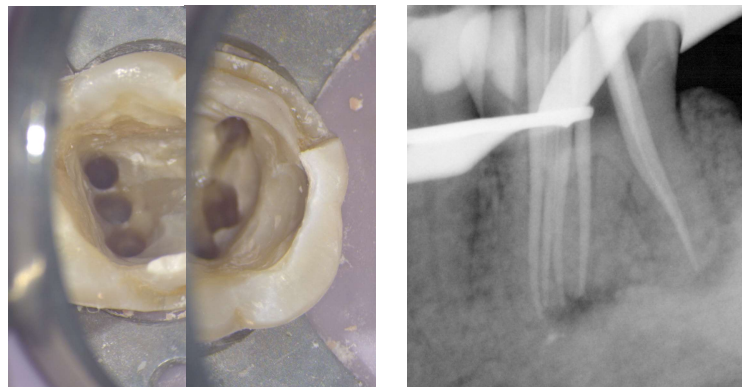
Michael P. Dyriw, D.D.S., M.S.

Middle Mesial Canals in Lower Molars

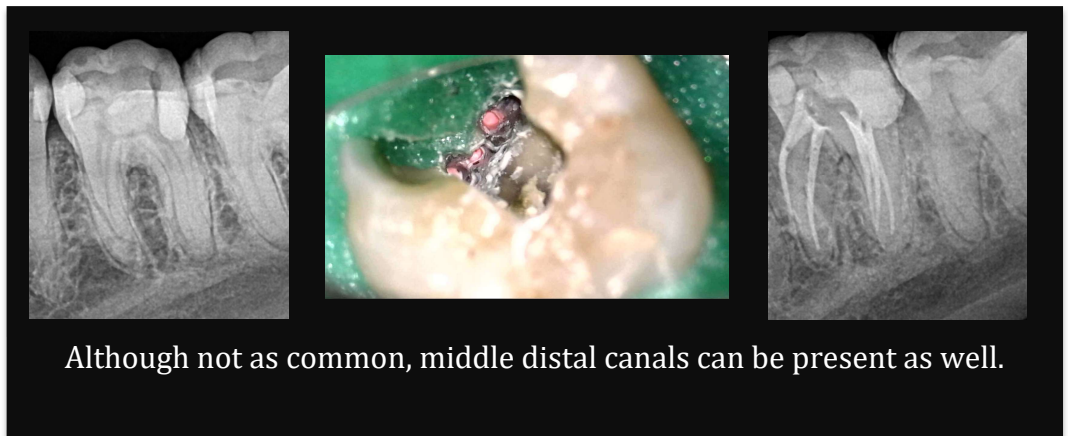
A middle mesial (MM) canal sometimes is present in the developmental groove between the MB and ML canals. Often times when this groove is prominent, I will trough it with either ultrasonics or a small round bur (Munce burs are great for this). I also notice a higher presence when the MB and ML canals are rather far apart. High magnification and illumination is essential to avoid perforation and its subsequent complications. Early studies demonstrate that success in locating and accessing a middle mesial canal has been very low, ranging between 1% and 25% but more recent studies show that the middle mesial canal was present in 46.2% of mandibular molars.¹ They also concluded a significantly higher incidence in younger patients. I find this is likely because the tooth hasn't yet begun to calcify. Although a middle distal canal is less likely, it can still be out there!



Middle
Mesial
Canals



This was a unique case with three mesial and three distal canals.



Although not as common, middle distal canals can be present as well.

1. Azim A, Deutsch A, Solomon C: Prevalence of Middle Mesial Canals in Mandibular Molars after Guided Troughing under High Magnification: An In Vivo Investigation. J Endod 41 (2), 2015.